

The Citagenix Clinical Report

Innovative and unique solutions to your surgical needs

Issue 5

Guided Tissue Regeneration Can Save Endo-perio Compromised Cases

Ari Gold, D.D.S., D.ENDO, F.R.C.D.(C), Toronto, Ontario

Guided Tissue Regeneration (GTR) can promote or guide the proliferation of periodontal ligament cells and attachments onto denuded root surfaces. The use of a biocompatible, resorbable membrane provides for the extensive regeneration of the attachment apparatus without the interference of faster regenerating epithelial cells. This is a form of selective cell repopulation. The use of DFDBA (Demineralized Freeze Dried Bone Allograft) materials can add an osteoconductive and osteoinductive component to facilitate the bone regeneration process.

A 32 year old male patient was referred for retreatment of tooth # 31. This tooth has a history of trauma at age 12 and was endodontically treated 2 years ago (fig.1). Patient now has a periapical radiolucency, labial sinus tract and labial periodontal pocket probing to apex of tooth. Endodontic treatment appears to have been performed at or above the accepted standard of care. The treatment plan involved exploratory periapical surgery. The patient was made aware of a high likelihood of a root fracture finding.

The patient was injected with 3.6cc Ultracaine with 1:100,000 epinephrine. A full thickness flap was elevated and reflected. Apical curettage was performed and the root was examined under a surgical operating microscope. The entire labial surface of the # 31 root was totally denuded of bony attachment. The root showed no evidence of fracture. The apical lesion was extensive enough to clearly see the lateral aspects of the roots of # 32 and # 41.

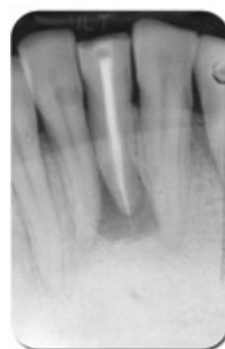
The root apex was retrofilled using IRM (a zinc oxide-eugenol intermediate restorative material, Dentsply Caulk). DynaGraft®II Gel (Citagenix Inc., Montreal, Quebec) was used to augment the periapical surgical site. DynaGraft®II is a bio-assayed DFDBA in a gel that stiffens in situ. With simple instrument or finger manipulation, the material can be molded to augment the deficient periapical area. Once in position, the viscosity of DynaGraft®II reduces the risk of migration during final placement, irrigation and flap closure. Because DynaGraft®II is a demineralized bone graft material, immediate post-operative radiographs will show the augmented site as radiolucent (fig. 2). The radiographs will appear more radiopaque as the bone augmentation material turns over into new, vital, mineralized bone in the short term (2 – 4 months).

A 30x40mm Neomem™ (Citagenix Inc., Montreal, Quebec) GTR resorbable collagen membrane was trimmed and placed along the labial surface of the bone. The membrane will assist in bone graft containment and will aid in eliminating connective tissue and epithelial invagination of the surgical site. Reapproximation of the flap was achieved with tension-free primary closure.

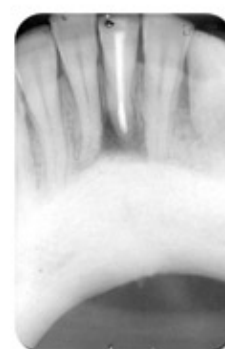
The patient was prescribed post-op medications: Clindamycin 150mg qid for 10 days, Peridex mouth rinse bid for 30 days and Tylenol 3 q4h as needed for pain.

Healing was uneventful and the three month post-op clinical evaluation showed significant periapical bone fill with no evidence of a sinus tract and labial periodontal probing depth of 2mm (fig. 3).

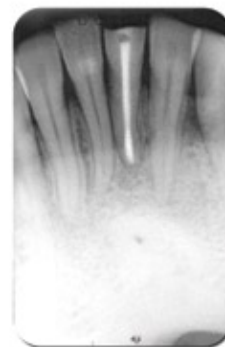
Guided Tissue Regeneration and Guided Bone Regeneration can prove invaluable in endodontic/periodontal cases that may otherwise have a poor prognosis which may ultimately lead to tooth loss. Augmentation materials can assist in the regeneration of new attachment cells and bony support for previously compromised cases.



1. Pre-op



2. Immediate post-op



3. Three months post-op