

Autogenous bone and platelet-rich plasma (PRP) in the treatment of intrabony defects

Czuryszkiewicz-Cyrana J*, Banach J*

Department of Parodontology, Pomeranian Medical University in Szczecin, Poland

Abstract

Purpose:

- obtaining an answer to the question whether autogenous bone in combination with PRP give a therapeutic effect in the form of periodontal ligament attachment regeneration,
- defining the degree of elimination of a convenient environment for subgingival bacterial plaque by reduction of periodontal pocket depth and periodontitis.

Material and methods: Twenty-six systematically healthy patients with diagnosed chronic and advanced periodontitis (24 females and 2 males) were selected for the study. In general 72 periodontal infrabony pockets were treated.

Clinically the following indexes were examined and measured:

1. Plaque Index by Silness and Loe
2. Sulcus Bleeding Index by Mühlemann and Son
3. Clinical Attachment Level (mm)
4. Pocket Depth (mm)
5. Gingival Recession (mm)
6. Tooth mobility with the use of Periotest
7. Degree of alveolar bone loss with the use of Engelberger, Marthaler and Rateitschak index – EMR Index.

Results: At 12 months after treatment the following results were noted:

- mean value of attachment level regeneration 3.47 mm
- mean value of pocket depth decreased by 3.7 mm
- mean value of tooth mobility reduction by 48.3%
- regeneration of alveolar bone by 9.24%.

Conclusions:

1. Autogenous bone with added PRP in treatment of intrabony defects caused by periodontitis have given significant clinical improvement of the periodontal tissues.
2. The combination of PRP and autogenous bone caused the elimination of a convenient environment for subgingival bacterial plaque eliminating periodontitis.

Key words: Widman's procedure, bone regeneration, autograft bone, platelet-rich plasma.

Introduction

Existing inflammation of the periodontium leads to destruction of periodontal tissues often causing a loss of some or even all teeth, whereas untreated vertical bone defects lead to a serious function impairment of the stomatognathic system. An important supplement of general complex periodontal treatment is periodontal surgery. Thanks to these periodontal surgical procedures there is a chance for restoring tooth supporting tissues. Up-to-date surgical treatment methods allow to avoid unwanted teeth extraction and widen possibilities of stomatognathic system rehabilitation.

The study aim was to:

- obtain an answer to the question whether cancellous cortical bone in combination with PRP give a therapeutic effect in the form of periodontal ligament regeneration,
- define the degree of elimination of a convenient environment for subgingival bacterial plaque by reduction of periodontal pocket depth and periodontitis.

Material and methods

Twenty-six systematically healthy patients with diagnosed chronic and advanced periodontitis (24 females and 2 males)

* CORRESPONDING AUTORS:

Janina Czuryszkiewicz-Cyrana, Jadwiga Banach
Department of Parodontology
Pomeranian Medical University in Szczecin
al. Powstańców Wlkp. 72, 70-111 Szczecin, Poland
Fax: 091 466 17 45

Table 1. Mean values of chosen clinical parameters at different periods of observation after implantation of autogenous bone with added PRP

Measured parameters	Before surgery	3 months after surgery	6 months after surgery	12 months after surgery
Number of treated periodontal pockets	72	72	72	72
PI	0.60	0.47	0.38	0.32
SBI	1.36	0.76	0.36	0.09
CAL	8.41	5.34 (+36.8%)	5.29 (+37.3%)	4.94 (+40.8%)
PD	6.62	3.28 (+50.0%)	3.18 (+51.4%)	2.92 (+55.2%)
REC	2.01	2.32 (+26.0%)	2.26 (+23.3%)	2.14 (+18.7%)
Tooth mobility	20.03	15.76 (24.5%)	13.01 (36.8%)	10.35 (48.3%)
EMR	41.15%	n.d.	n.d.	50.39%

n.d. – no data

were selected for the study, mean age 46,8 years, range from 21 to 62 years.

Patients were selected basing on clinical periodontal examination and panoramic radiogram analysis. Exclusion criteria consisted of patients with typical horizontal alveolar bone defects. Inclusion criteria consisted of patients having vertical intrabony defects. Generally 72 periodontal infrabony pockets were treated, 53 by upper teeth (25 by incisors, 5 by canines, 10 by premolars, 13 by molars) and 19 periodontal pockets localized in the mandible (1 by a canine, 8 by premolars, 10 by molars). The examined group consisted of twenty-one 3-wall defects, fifty 2-wall defects and one 1-wall defect.

Clinically the following indexes were examined and measured:

1. Plaque Index (PI) of Silness and Løe [1]
2. Sulcus Bleeding Index (SBI) of Mühlemann and Son [2]
3. Clinical Attachment Level – CAL (mm)
4. Pocket Depth – PD (mm)
5. Gingival Recession – REC (mm)
6. Tooth mobility with the use of Periotest
7. Degree of alveolar bone loss with the use of Engelbelger, Marthaler and Rateitschak Index – EMR Index [3,4]

Patients were informed as to the character and aim of the study and signed an informed consent. Initial therapy consisted of oral hygiene instructions, tooth brushing using the roll method and cleaning of interdental spaces using a system individually chosen for the patients' needs. Scaling and root planning was performed. Occlusal adjustment of fillings and prostodontic restorations was carried out, also elimination of iatrogenic irritative factors, carries was treated, endodontical treatment was carried out, occlusal analysis and where necessary occlusal adjustment was performed.

Four to six weeks following the first hygienic phase a control hygiene examination was carried out among the patients using the Plaque Index. Only patients with good oral hygiene (PI: 0.4–0.6) were qualified for surgical treatment [5].

Directly before surgery 8.5 ml of blood were drawn from the antecubital vein from each patient to a glass tube containing a CPDA solution as an anticoagulant. A special glass tube set PRP-kit (Curasan Pharma) and laboratory centrifuge MPW – 221/MPW – 223 (Curasan Pharma) were used to obtain separation of basic blood fractions (PRP) from the patients blood.

Osseous tissue was taken directly from the surgical site with the use of Safescraper (C.G.M.s.p.a. Divisione Medicale Meta).

In all patients with diagnosed intrabony defects the modified flap Widmans procedure was carried out and autogenous bone was implanted with added platelet-rich plasma (PRP).

Results

The results showed that the treated patients maintained good oral hygiene. Mean value of Plaque Index (PI) achieved before treatment was 0.6 and at 12 months was reduced to 0.3. It was observed that the Sulcus Bleeding Index (SBI) was reduced after 12 months to a value of 0.1 (*Tab. 1*).

Comparing mean values of clinical attachment level, a significant reduction was observed in all study periods, giving evidence for its regeneration (*Fig. 1*). At 6 months postoperatively clinical attachment gain was observed of mean value 3.1 mm and at 12 months postoperatively this value reached 3.5 mm.

One of the desired outcomes of periodontal regenerative procedures is pocket depth reduction. In the study after a period of 6 months the mean pocket depth value was 3.2 mm, after 12 months a reduction by 2.9 mm was observed (*Fig. 2*). The total value of pocket depth reduction after a year was 3.7 mm. This

Figure 1. Mean values of changes in attachment level CAL (in mm) at determined observation periods

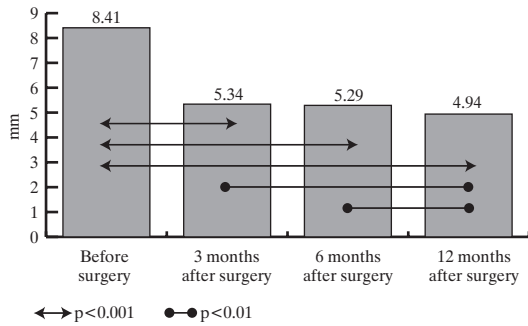


Figure 2. Mean value of periodontal pocket depth PD (in mm) at determined observation periods

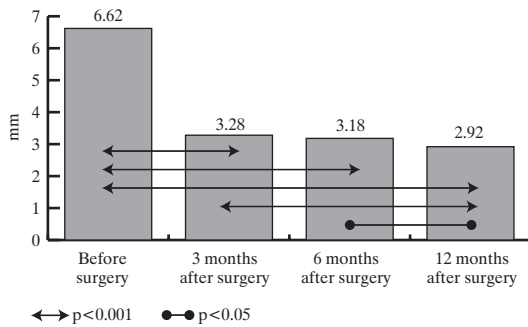


Figure 3. Values of the radiological alveolar bone defect index EMR in percentage

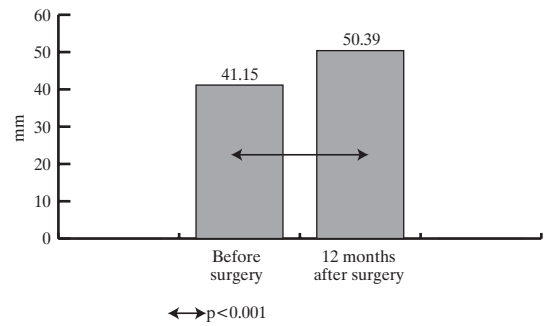
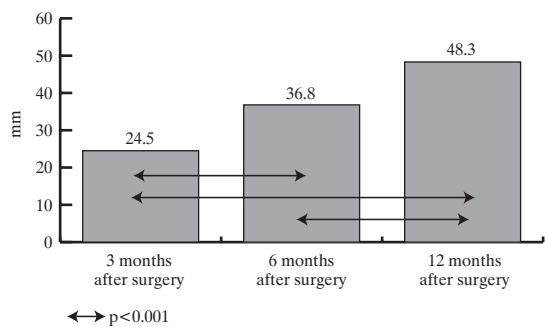


Figure 4. Reduction of tooth mobility at different periods of observation compared to baseline (in percentage)



shows that a combination of autogenous bone implantation and PRP is a highly effective treatment.

Carried out analysis of gingival recession showed an increase by 0.13 mm after 12 months postoperatively in comparison to baseline (Tab. 1).

To define the degree of bone defect progression the EMR index was used. According to this index the correct value for alveolar bone level both in the mandible and maxilla is in the range of 60.0% to 70.0% [3,4]. The EMR value before treatment was 41.15%. At 12 months postoperatively the EMR index presented the value of 50.4% (Fig. 3). The obtained results show that significant alveolar bone regeneration was achieved of 9.2%.

An important outcome of surgical periodontal treatment is tooth mobility reduction, what gives a great chance for tooth maintenance or even its incorporation in prosthetic treatment. The study results have confirmed that treatment of periodontal infrabony pockets with the use of autogenous bone and PRP caused reduction of tooth mobility by a value of 48.3% (Fig. 4).

Discussion

Process complexity undergoing during periodontal regeneration is the cause for utilizing a variety of biomaterials, which induce mineralized tissues (cementum and alveolar bone) and soft tissues (periodontal ligament, periodontium) formation. The aim of regenerative periodontal procedures is to achieve regeneration of all periodontal tissues, that is tissues, which are

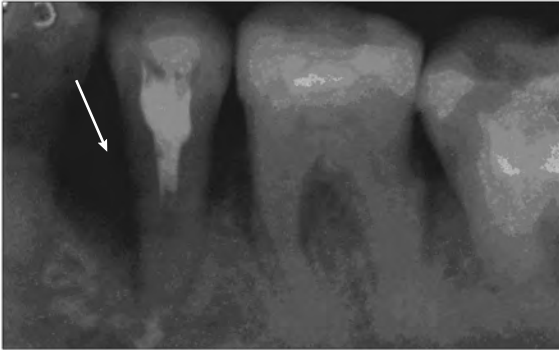
functionally and structurally identical with those lost as a result of a disease process [6,7]. Unfortunately it is impossible to supply documentary evidence for periodontal regeneration in clinical conditions. It also has to be emphasized that reduction of periodontal pocket depth after carried out treatment does not allow to clearly ascertain that a new periodontal ligament has been formed. In some cases clinical measurements are not consistent with histological findings [8] and clinical attachment gain does not always imply regeneration of the periodontal ligament at the histological level [9].

The most biocompatible implant material used in treatment of intrabony bone defects caused by periodontitis is autogenous bone. Carraro at al. [10] performed treatment of intrabony defects using autogenous bone and 12 months postoperatively recorded regeneration of the periodontal ligament by 2.88 mm. In a study by Froum at al. [11] treatment with autogenous bone was followed by re-entry surgery and presented regeneration of alveolar bone by 2.98 mm while results of open curettage showed bone regeneration of only 0.66 mm. A more intensive bone formation, of 3.4 mm after implantation of autogenous bone, was observed by Hiatt at al. [12].

Recently developed procedures for treatment of intrabony defects utilize platelet-rich plasma (PRP), a concentrated suspension of growth factors. Various studies have preclinically examined the use of growth factors on animals [13-18]. Local application of growth factors is used to promote healing, especially periodontal regeneration. Many studies have shown that PDGF, IGF, TGF-β are found in PRP and the use of these factors has led to promising results also in humans [19-21].

Figure 5. A radiogram showing a bone defect around tooth 35 treated with autogenous bone and PRP

a) before treatment



b) 12 months after treatment

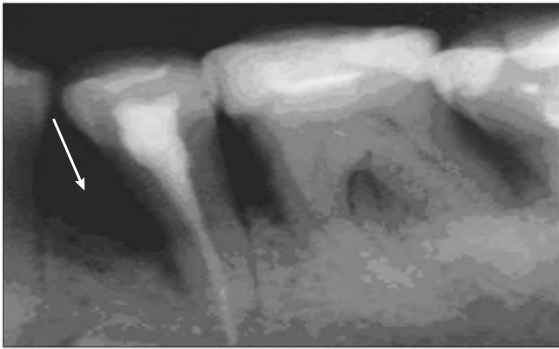
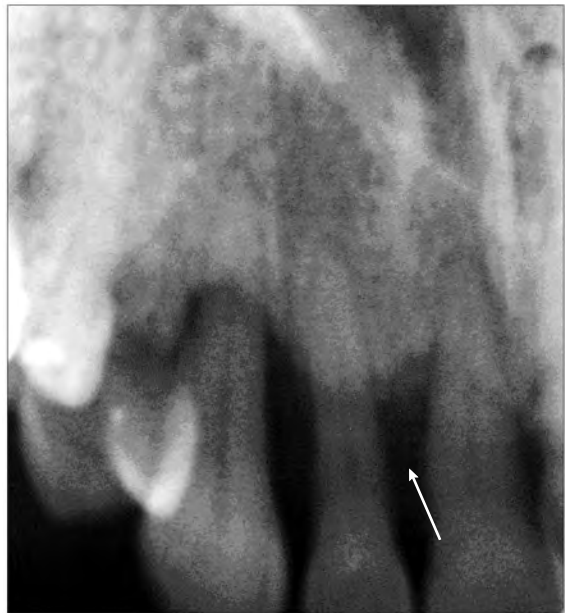
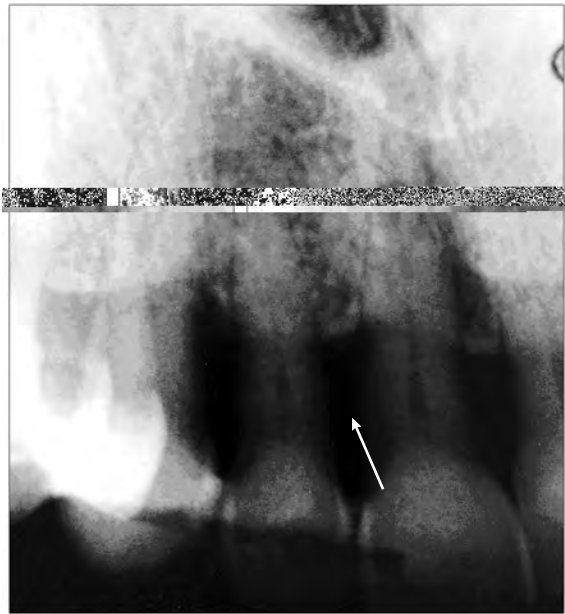
Figure 6. A radiogram showing a bone defect around tooth 12 treated with autogenous bone and PRP

a) before treatment



b) 12 months after treatment



A combination of these growth factors with biomaterials can stimulate regeneration of bone [19-21]. Bone is constantly remodeled by cycles of resorption and formation of its structure and both cycles of this remodeling are controlled by locally released growth factors [22].

Very few studies have been carried out with the purpose to estimate the efficiency of use of combination of PRP and autogenous bone on bone regeneration. Studies by Marx *et al.* have given evidence that the addition of PRP to milled bone graft obtained from the posterior ilium increased the rate of bone formation and the final quantity of bone formed at 6 months postoperatively [21]. These authors have shown that bone grafts with added PRP presented with increased bone density (74.0% +/- 11.0%) in comparison with grafts without PRP (55.1% +/- 8.0%). Results of the above mentioned studies suggested that growth factors accelerate and intensify alveolar bone regeneration. Similar conclusions have been published by Fennis *et al.* [23] in a study carried out on bone regeneration in a goat.

In opposition to these findings stands Aghaloo *et al.* [24]. Basing on carried out studies these authors suggest that there is no evident relevance between PRP additions to bone grafts and increased bone regeneration. The authors based this evaluation on a study of regeneration process effectiveness on rabbits cranial vault. Similar observations were published by Jakse *et al.* [25] in an experimental study on autogenous sinus grafts in sheep.

Results of the present study confirm data obtained by Aghaloo *et al.* and give evidence of not significant effectiveness

of autogenous bone with PRP in treatment of intrabony defects resulting from periodontitis. Results of the present study indicate alveolar bone regeneration in the range of 10.0% (9.24%), while more effective results have been obtained with guided tissue regeneration of periodontal tissues with the use of membranes, regeneration methods and biomaterials [9,19,20].

Autogenous bone and PRP are autologous preparations without antigenicity, this allows to eliminate biological concerns such as immunogenic reactions and disease transmission. Moreover, autologous bone cells are vital, contain receptors of growth factors PDGF and TGF- β [21] and also show osteogenetic and osteoinduction action.

References

1. Silness J, Loe H. Periodontal disease in pregnancy II Correlation between oral hygiene and periodontal condition. *Acta Odont Scand*, 1964; 22: 121-35.
2. Mühleemann HR, Son S. Gingival sulcus bleeding – a leading symptom in initial gingivitis. *Helv Odont Acta*, 1971; 15: 107-13.
3. Engelberger A, Rateitschak K, Marthaler T. Zur Messung des Parodontalen Knochenschwundes. *Helv Odont Acta*, 1963; 4: 34.
4. Rateitschak K, Marthaler T, Engelberger A. Beziehungen zwischen Entzündungsgrad der Gingiva. Knochenschwund und Zahnbeweglichkeit bei parodontalen Erkrankungen. *Helv Odont Acta*, 1964; 8: 26.
5. Banach J. Most important hygiene elements in prophylaxis and treatment of periodontopathy. *Mag Stom*, 2002; 12: 15-20.
6. Camelo M, Nevins ML, Schenk RK, Lynch SE, Nevins M. Periodontal regeneration in human Class II furcations using purified recombinant human platelet-derived growth factor-BB (rhPDGF-BB) with bone allograft. *Int J Periodontics Restorative Dent*, 2003; 23: 3, 213-25.
7. Tözüm T, Demiralp B. Platelet-Rich Plasma: a promising innovation in dentistry. *J Can Dent Assoc*, 2003; 69: 10, 664-664h.
8. Harris RJ. A combination graft of allographic bone, alloplastic substance and tetracycline In addition with guided tissue regeneration (GTR) in treatment of furcations: a histological estimation in humans – case report. *Quintessence Periodontologi-Implanty*, 2003; 2: 103-8.
9. Camargo PM, Lekovic V, Weinlaender M, Vasilic N, Madzarevic M, Kenney EB. Platelet-rich plasma and bovine porous bone mineral combined with guided tissue regeneration in the treatment of intrabony defects in humans. *J Periodont Res*, 2002; 37: 300-6.
10. Carraro JJ, Sznajder N, Alonso CA. Intraoral cancellous bone autografts in the treatment of intrabony pockets. *J Clin Periodontol*, 1976; 3: 104-9.
11. Froum SJ, Ortiz W, Witkin RT, Thaler R, Scopp LW, Stahl SS. Osseous autografts. III. Comparison of osseous coagulum – bone blend implants with open curettage. *J Periodontol*, 1976; 47: 287-94.
12. Hiatt WH, Schallhorn RG. Intraoral transplants of cancellous bone and marrow in periodontal lesions. *J Periodontol*, 1973; 44: 194-208.
13. Cho M, Lin W, Genco R. Platelet-derived growth factor modulated guided tissue regenerative therapy. *J Periodontol*, 1995; 66: 522-30.
14. Giannobile WV, Hernandez RA, Finkelman RD, Ryan S, Kiritsy CP, D'Andrea M, Lynch SE. Comparative effects of platelet-derived growth factor-BB and insulin-like growth factor-I, individually and in combination, on periodontal regeneration in *Macaca fascicularis*. *J Periodont Res*, 1996; 31: 301-12.
15. Hosokawa R, Kikuzaki K, Kimoto T, Matsuura T, Chiba D, Wadamoto M, Sato Y, Maeda M, Sano A, Akagawa Y. Controlled local application of basic fibroblast growth factor (FGF-2) accelerates the healing of GBR. An experimental study in beagle dogs. *Clin Oral Implants Res*, 2000; 11(4): 345-53.
16. Kimoto T, Hosokawa R, Kubo T, Maeda M, Sano A, Akagawa Y. Continuous administration of basic fibroblast growth factor (FGF-2) accelerates bone induction on rat calvaria – an application of a new drug delivery system. *J Dent Res*, 1998; 77(12): 1965-9.
17. Lynch S, Buser D, Hernandez R, Weber H, Stich H, Fox C, Williams R. Effects of the platelet-derived growth factor/insulin-like growth factor-I combination on bone regeneration around titanium dental implants. Results of a pilot study in beagle dogs. *J Periodontol*, 1991; 62(11): 710-6.
18. Lynch SE, de Castilla GR, Williams RC, Kiritsy CP, Howell TH, Reddy MS, Antoniadis HN. The effects of short-term application of a combination of platelet-derived and insulin-like growth factors on periodontal wound healing. *J Periodontol*, 1991; 62(7): 458-67.
19. Camargo PM, Lekovic V, Weinlaender M, Vasilic N, Madzarevic M, Kenney EB. Platelet-rich plasma and bovine porous bone mineral combined with guided tissue regeneration in the treatment of intrabony defects in humans. *J Periodont Res*, 2002; 37: 300-6.
20. Lekovic V, Camargo PM, Weinlaender M, Vasilic N, Kenney EB. Comparison of Platelet-Rich Plasma, bovine porous bone mineral, and guided tissue regeneration versus Platelet-Rich Plasma and bovine porous bone mineral in the treatment of intrabony defects: a reentry study. *J Periodontol*, 2002; 73: 198-205.
21. Marx RE, Carlson ER, Eichstaedt RM, Schimmele SR, Strauss JE, Georgeff KR. Platelet rich plasma: Growth factor enhancement for bone grafts. *Oral Surg Oral Med Oral Pathol Oral Radiol Endod*, 1998; 85: 638-46.
22. Jiang D, Dziak R, Lynch SE, Stephan EB. Modification of an osteoconductive anorganic bovine bone mineral matrix with growth factors. *J Periodontol*, 1999; 70: 834-9.
23. Fennis J, Stoelinga P, Jansen J. Mandibular reconstruction: a clinical and radiographic animal study on the use of autogenous scaffolds and platelet-rich plasma *Int J Oral Maxillofac Surg*, 2002; 31: 3, 281-6.
24. Aghaloo T, Moy P, Freymiller E. Investigation of platelet-rich plasma in rabbit cranial defects: A pilot study. *J Oral Maxillofac Surg*, 2002; 60: 10, 1176-81.
25. Jakse N, Tangl S, Gili R, Berghold A, Lorenzoni M, Eskici A, Haas R, Pertl C. Influence of PRP on autogenous sinus grafts. An experimental study on sheep. *Clin Oral Impl Res*, 2003; 14: 578-83.